

Elayne J. Pope,<sup>1</sup> M.A. and O'Brian C. Smith,<sup>2</sup> M.D.

## Identification of Traumatic Injury in Burned Cranial Bone: An Experimental Approach\*

**ABSTRACT:** Interpreting patterns of injury in victims of fire-related deaths poses challenges for forensic investigators. Determining manner of death (accident, suicide or homicide) using charred remains is compounded by the thermal distortion and fragmentation of soft and skeletal tissues. Heat degrades thin cranial structures and obscures the characteristic signatures of perimortem ballistic, blunt, and sharp force trauma in bone, making differentiation from thermal trauma difficult. This study documents the survivability and features of traumatic injury through all stages of burning for soft tissue reduction and organic degradation of cranial bone.

Forty cadaver heads were burned in environments simulating forensic fires. Progression of thermal degradation was photographically documented throughout the destructive stages for soft tissues and bone to establish expected burn sequence patterns for the head. In addition to testing intact vaults, a percentage were selectively traumatized to introduce the variables of soft tissue disruption, fractures, impact marks, and incisions throughout the cremation process. Skeletal materials were recovered, reconstructed, and correlated with photographs to discern burn patterns and survivability of traumatic features.

This study produced two important results: (1) Identification of preexistent trauma is possible in reconstructed burned cranial bone. Signatures of ballistic (internal and external bevel, secondary fractures), blunt force (impact site, radiating fractures), and sharp force (incisions, stabs, sectioning) survive the cremation process. (2) In non-traumatized specimens, the skull does not explode from steam pressure but does fragment as a result of external forces (collapsed debris, extinguishment methods) and handling. The features of both results are sequentially described throughout the progression of thermal destruction.

**KEYWORDS:** forensic science, forensic anthropology, forensic pathology, criminalistics, burned bone, cremation, perimortem trauma, exploded skull, ballistic injury, blunt force trauma, sharp force trauma

While the majority of fire deaths occurring in homes and vehicles are accidental, some are intentionally set to obliterate homicidal acts, personal identity, or incriminating evidence. Recognizing these acts becomes more difficult when burning affects the soft and hard tissues normally examined for trauma analysis. With respect to the head, identity and injuries are readily obscured because of its early structural vulnerability when the thin insulation of skin and muscle burns away, exposing bone to progressive degradation of organic and inorganic components. Loss of organic components in the thin cranial bone leaves them fragile and susceptible to additional erosion or fracturing from heat, any impact occurring as part of the fire scene, or the influence of extinguishment and recovery methods. In many instances these post-traumatic artifacts are recognizable, but the danger lies with their ability to either mimic or obscure antecedent traumatic features.

Fire death investigations involve collaborative efforts among law enforcement, arson investigators, forensic pathologists, anthropologists, and odontologists to reconstruct circumstances of the scene, manner of death, and victim identity. Many interpretive concepts and language for analyzing features of burned remains were born out of archaeological research reports (1–3) or clinical findings at

autopsy (4–6). These publications established the current terminology used for describing fire damage to soft tissue and bone. More recently, experimental models of burn trauma have produced analytical tools founded on scientific observation of the features distinguishing traumatic injury (7–10), fleshed versus dry (11–13), and analysis of cremated bone (14–17,33).

Most published research addresses analysis of burn patterns for long bone models; little has focused on cranial structures. The head is not only a frequent target of injury, it is also one of the most thermally susceptible, making critical analysis vital. In order to differentiate burn patterns of the traumatized head from purely thermal effects, it is necessary to develop an expectation of features produced by thermal damage. Once typical cranial patterns are modeled then the effects of traumatic injury will appear as obvious deviations from the norm.

Analysis of heat-related skeletal trauma must begin by understanding the insulative protection bone is afforded by skin, muscle, and fat. Differential thicknesses and anatomical distributions of soft tissue structures determine how, where, and at what point bone becomes exposed. Hypotheses of cranial burn patterns for this research were based upon evaluating standardized tissue thickness (18,19) used in facial reconstruction. Burn patterns are commonsensical, hence predictable, with the understanding that thin areas of the upper face and scalp are more vulnerable to early thermal destruction than the thicker musculature of the lower face and nape of the neck. Beginning with superficial burns to skin, thermal destruction systematically reduces soft tissue layers and bone by pyrolyzing all organic materials.

Clinical publications describe dermal burns through the production of blisters, color changes, and skin splitting (4–6). Depending upon size and anatomical placement, most layers of soft tissues

<sup>1</sup> Anthropology Department, University of Arkansas, 330 Old Main, Fayetteville, AR 72701.

<sup>2</sup> University of Tennessee Health Sciences Center, Regional Forensic Center, 1060 Madison Ave., Memphis, TN 38104.

\* Financial disclosure supported in part by Forensic Sciences Foundation Lucas Research Grant, and was presented at the 55th American Academy of Forensic Sciences, Chicago, IL, 20 February 2003.

Received 25 Aug. 2003; and in revised form 21 Dec. 2003; accepted 31 Dec. 2003; published 7 April 2004.

TABLE 1—Variables of simulated traumatic injury in human cranial vaults.

Heads Tested*	Analyzed*	Trauma Type	Tool or Weapon	Direction	Wound Analysis
16	13	ballistic	entrance wounds	multiple directions	17
			exit wounds	multiple directions	9
			9 mm	multiple directions	10
			10 mm	multiple directions	4
8	7	blunt	skillet (broad surface)	multiple directions	6
			hammer	multiple directions	1
			pry bar/tire iron	multiple directions	3
			unrestricted position	A/P and lateral impact	9
			restricted position	A/P and lateral impact	2
6	6	sharp	knife	multiple directions	3
			machete	multiple directions	2
			scalpel	multiple directions	2
			Stryker saw	standard autopsy cuts	5
			toolmarks	multiple directions	6
10	10	control	no trauma	no trauma	None

\* 40 total heads tested; 36 analyzed after burning.

undergo dehydration, contraction, and charring with loss of tissue mass (5–7,21). Once exposed, bone undergoes a set sequence of color change that signifies stages of organic pyrolysis (collagen, proteins, lipids, and water) rather than an indicator of temperature. The same range of color changes in bone were observed in specimens burned both at 400°F and 1600°F (204°C and 871°C). The first transitional color follows contours of soft tissue withdrawing around bone from heat exposure. This temporary boundary against unburned bone, still protected within soft tissue, changes slightly to a lighter more translucent tone and is the initial stage of organic coagulation. A more recognizable color change of black from charring (11–13) follows as an intermediate process involving organic pyrolysis and carbonization. The final stage is calcination, where bone color varies among white, gray, and rarely blue (11–13,15), signifying complete pyrolysis of all organic materials and leaving bone an inorganic, fragile, glass-like structure. Calcined bone is notorious for exhibiting a variety of heat fractures, deformation, shrinkage, and fragmentation (2,15,20). The ability to differentiate thermal features from traumatic signatures was further investigated in cranial bone.

To date, burn patterns of soft tissue and bone have not been scientifically investigated or documented for the human head. Our primary goal is to provide analytical tools for interpreting the expected sequence of thermal destruction represented in forensic cases. Features of preexisting trauma (ballistic, blunt, and sharp force) become recognizable deviations from this model. Of secondary emphasis is the survivability of known traumatic signatures during tissue burning and retention of injury characteristics in cremated cranial bone.

## Materials and Methods

This actualistic study attempts to replicate typical structural or vehicular fires to accurately reproduce the heat-related changes in cranial soft tissue and bone with and without the presence of antecedent trauma. While crematorium resources are available and may seem ideal, it is important to utilize open-air fires reproducing forensic casework in order to accurately observe and record a continuum of subtle changes as they occur, rather than intermittently collecting information through the door of a kiln. Patterned after observation-based human decomposition research (31,32), a similar inductive research approach was used to establish sequences of thermal destruction for the head. Data were actively collected

during all stages of burning and correlated with cremated skeletal remains following fragmentary reconstruction.

A total of 40 unembalmed human heads from anatomical gift donations were evaluated for ballistic trauma, blunt force trauma, sharp force trauma, and non-traumatized controls (Table 1). Procedures for using human materials in this research comply with IRB Protocol (#03384). Prior to and/or following placement of known trauma, heads were documented with lateral and anterior-posterior radiographs. Once fracture patterns and sites of impact were recorded on X-ray, each head was burned under conditions simulating a forensic fire while photographically recording soft tissue reactions, followed by burn patterns in cranial bone. Blunt and ballistic injuries were produced in 24 cadaver heads, and a variety of sharp force trauma was created in six crania. Ten non-traumatized heads attached to intact bodies served as control specimens.

Ballistic trauma was extensively tested due to its prevalence in forensic casework and the confidence of producing complete fractures, with entrance, and sometimes exit injuries. Sixteen heads were positioned within a cotton-packed ballistic stop-box, targeting various orientations of the vault (anterior/posterior, superior/inferior, and left/right). In some cases additional gunshot wounds were produced to reconstruct wound sequence in calcined bone (24,25). Ballistic specimens were produced by handguns using either 9 mm (parabellum) or 10 mm ammunition with full metal jacket or jacketed hollow point bullets. Blunt force injuries were aligned along two anatomic planes (anterior/posterior and left/right) for eight heads. Some impacts were delivered to crania replicating dynamic forces to an unrestrained head with the slight mobility of an upright victim. Others simulated a collapsed victim with crania buttressed by a hard surface during impacts to create direct and indirect injuries. Blunt forces were delivered until fractures became discernable on radiographs. Selected instruments for blunt force injuries included those capable of producing specific patterns (hammer, pry bar or tire iron) and broad flat-surfaced objects (skillet). For six crania, randomly distributed sharp trauma was produced with scalpel incisions, knife cut marks, chop marks, and full-thickness sectioning by autopsy saw.

A range of materials was used to contain and maintain heat through combinations of wood, metal reflectors, charcoal, and accelerants. Documentation of time, duration, reactions of tissues, anatomical degradation, and origins of anatomical burn patterns became crucial to understanding how the human head, particularly bone, is consumed by fire. The expedient and dynamic process of destruction requires photographic sequencing of the entire burning

event and provides primary archival records for comparative analysis. Thermal modification was documented from ignition to extinguishment and endpoints varied from partial to full cremation in order to assess the stage and range of thermal degradation versus preservation of identifying characteristics in traumatic stigmata. General temperature ranges of 400°F to 1600°F (204°C to 871°C) monitored with pyrometric thermocouples were maintained to replicate forensic fires. Following extinguishment, fragmentary cranial remains were excavated, recovered, and brought to the osteology laboratory for accurate skeletal reconstruction and photographic correlation. The process of burning was fully documented for all heads, but not all crania structurally survived for the physical reconstruction and analysis. Several sustained extreme fragmentation from prolonged exposure to heat, mechanical fractures (fallen debris), or exaggerated fragility from disease, or degenerative changes (osteoporosis).

Prior to investigating traumatic injuries, it was necessary to establish expected heat-related changes to soft tissue and bone. This was accomplished by reviewing the photographic sequence of burning for soft tissues of the face and scalp of non-traumatized controls. This photographic essay evaluated the lacerations, incisions, and penetrations of traumatized soft tissues under the influence of heat. Images of soft tissue reduction were correlated with sequencing the exposure of bone and its subsequent expression of color changes. For calcined specimens lacking color variation, heat fractures were analyzed according to their location, progression, morphology, and type.

The heat-related effects in non-traumatized crania established controls, allowing comparison to features in the traumatized crania. Responses were correlated with known areas of trauma and evaluated for survivability of retained ballistic, blunt, or sharp force injury in bone. The traumatic changes in surviving skeletal specimens were evaluated with the naked eye, photographed using tangential lighting and microscopically surveyed under a  $\times 10$ – $\times 40$  operating scope. Following identification of known skeletal trauma, surrounding fracture sites were examined to determine relatedness to either trauma or expected heat-related changes. Primary fractures of entrance and exit wounds, impact sites, inward crushing, toolmarks, and cut marks were evaluated along with secondary features such as radiating and concentric fractures (22–30). Distinguishing features present in the morphology of fracture margins and impact sites allowed discrimination between traumatic and heat-related origin.

## Results

We first evaluated the thermal fractures in the ten control crania to establish expected patterns prior to identifying traumatic characteristics. The human head burns in relationship to the varied thickness and anatomic distribution of insulative skin, muscle, and fat covering the head and face. It also is uniquely subject to the rapid degloving of the scalp covering the vertex caused by dynamic retraction following skin splitting. Typically the superficial bony areas under the thin, uniform scalp and forehead are exposed first followed by the thicker muscular areas of the lower face. During the initial stages of firing, soft tissue structures of the face experiences a consistent sequence of changes.

Early heating produces transient bloating of the face, retraction of the lips, protrusion of the tongue, and shortening of the nose. Contemporaneously, skin and supporting soft tissues of the face shrink with a combination of color bands, skin splitting with retraction, and/or blistering. Color banding is the initial reaction to heat where skin experiences varying degrees of thermal alteration representing a progression of color (darkening from reds and browns to

black) based on position and orientation in the fire. Simply put, it is an advancing burn line indicating the thermal destruction of skin. Continued heat exposure blackens tissue from charring of organic materials as skin and muscle becomes carbonized, as does bone. Blistering follows color banding and is not to be confused with the early and superficial second-degree burn seen in the living. Moisture and gases expanding under layers of skin as it is heated raise the epidermis into oval or circular blisters. When they burst, a sharply defined outline remains, leaving underlying soft anatomy exposed to the heat. Skin splitting results as heat-induced contraction produces tensile forces exceeding the failure strength of the burned dermis; the ruptured margins pull away and uncover underlying fat, muscle, and hard tissues. This mechanism is responsible for the initial compromise of skin as elastic tension and shrinking create the openings and originates at points of weakness in the dermis including incisions, open wounds, blunt trauma, and scar tissue.

Once skin is breached, bone becomes vulnerable based upon protection conferred by the remaining tissues as heat continues to dehydrate, shrink, or consume the surrounding soft anatomy. Bare bone then undergoes the sequence of color changes reflecting progressive degradation of organic material, leaving it inorganic and brittle. Heat continually alters and reduces the organic component of bone, with recognizable and sequential color changes of light buff (initial organic degradation), black (carbonized organic destruction), and white/gray (calcined inorganic structure). This color banding remains as a permanent signature of thermal effect even after burned bones are processed free of soft tissue. Aggressive interactions among rapid heating, vigorous shrinking of soft tissue (including periosteum) and organic changes in the bone produce heat fractures in all stages of color change, but are especially prominent with calcination.

## Heat-Related Fractures

Discussion of traumatic signatures in burned cranial bone first requires an introduction to the mechanism, morphology, and identification of normal heat-related changes. Delamination is the most common heat-related fracture type observed in the skull. This presents in the external table as small tensile surface cracks and areas where the outer table shrinks, separates, and exposes the underlying diploe (Fig. 1). In advanced incineration, layers of the external table can curl and peel as it separates from the diploe. In several instances, delamination produced externally beveled features mimicking ballistic or blunt trauma complete with full thickness linear fractures and associated fragmentation. Delamination can occur during the fire with gradual fragmentation from thermal destruction, while cooling after the fire, or may be induced by any external force or postmortem handling of fragile calcined remains during extinguishment, recovery, transport, and analysis.

Advanced incineration and impacts from the surrounding dynamic fire environment may also produce full thickness fractures involving the inner table. Best observed in calcined bone, any complete defect during early stages of burning often has margins outlined in deep black from the pressurized venting of organic materials within the vault (Fig. 2). Examination of this feature and others discussed below are important since they are associated with known traumatic fractures, open sutures, and non-traumatic full thickness heat fractures of the skull.

Linear fractures either heat-related or of preexistent trauma fall into a gray area. These can occur during the earliest stage of burning as the organic content in bone is altered or reduced with resultant shrinking and cracking of bone. In broad areas of prolonged heat exposure, they may also radiate from charred black areas into



FIG. 1—Delamination is separation of external cranial table from underlying diploe resulting from heating and shrinking.



FIG. 2—Heat-related fractures and open sutures become impregnated with carbon from organic venting.

buff-colored bone undergoing initial thermal alteration. However, they do not extend into green unburned bone, as this is a definite feature of a preexisting fracture (Fig. 3).

Deep linear fractures sectioning all tables of cranial bone should be closely examined for similar morphologies along corresponding margins, in many cases a mirror image. Fracturing calcined bone

with thermal or mechanical forces produces well-defined sharp margins, often accompanied by deformation and shrinkage during later stages (Fig. 4). Traumatic fractures may have eroded, blunted, deformed, or even warped margins reflecting early and therefore prolonged thermal exposure, altering both external and internal tables. The difference becomes obvious following reconstruction, since



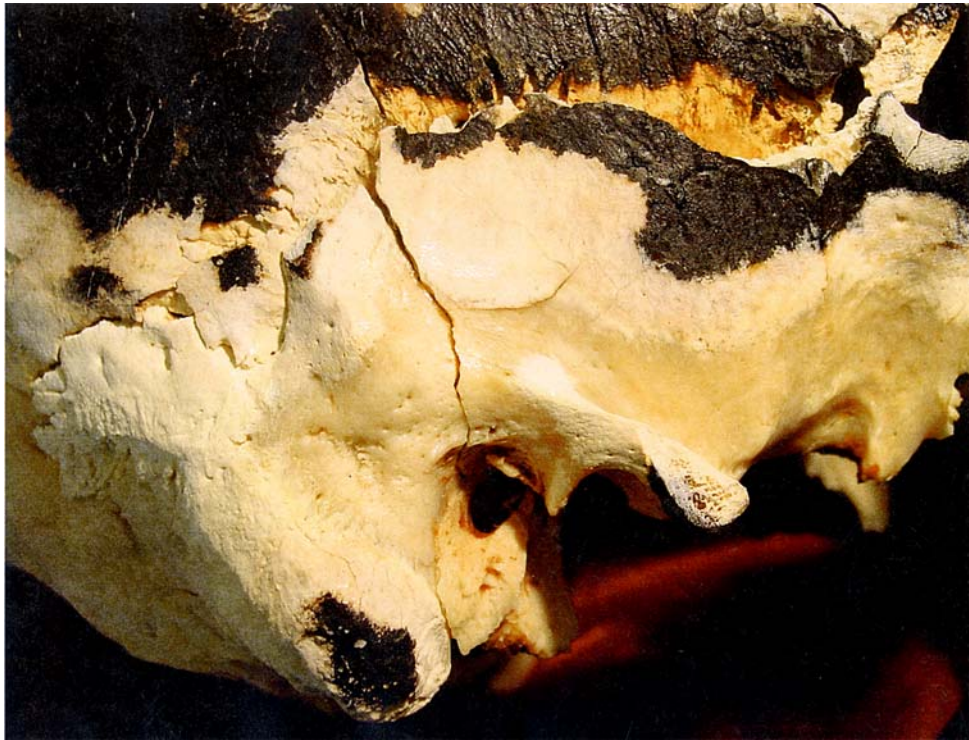

FIG. 3—Only traumatic preexisting fractures radiate into unburned bone.

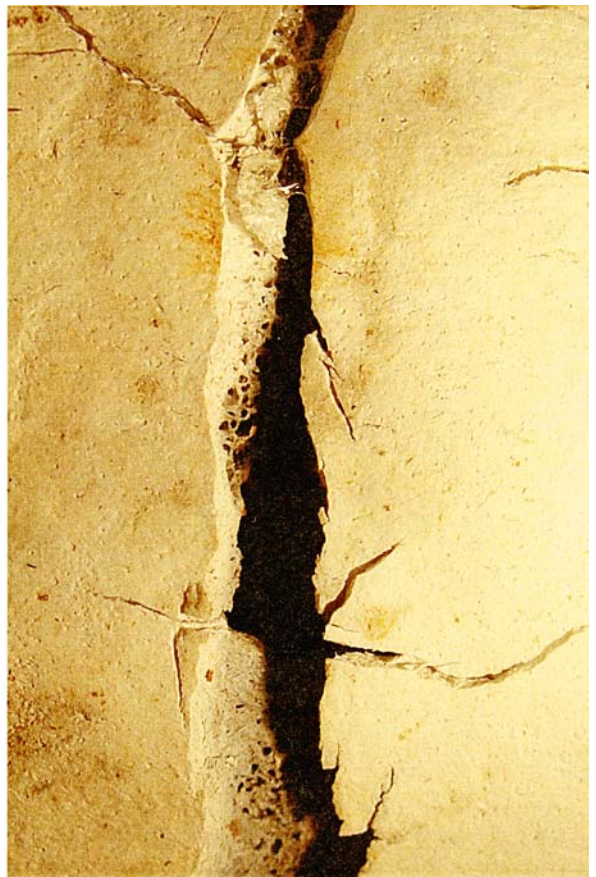
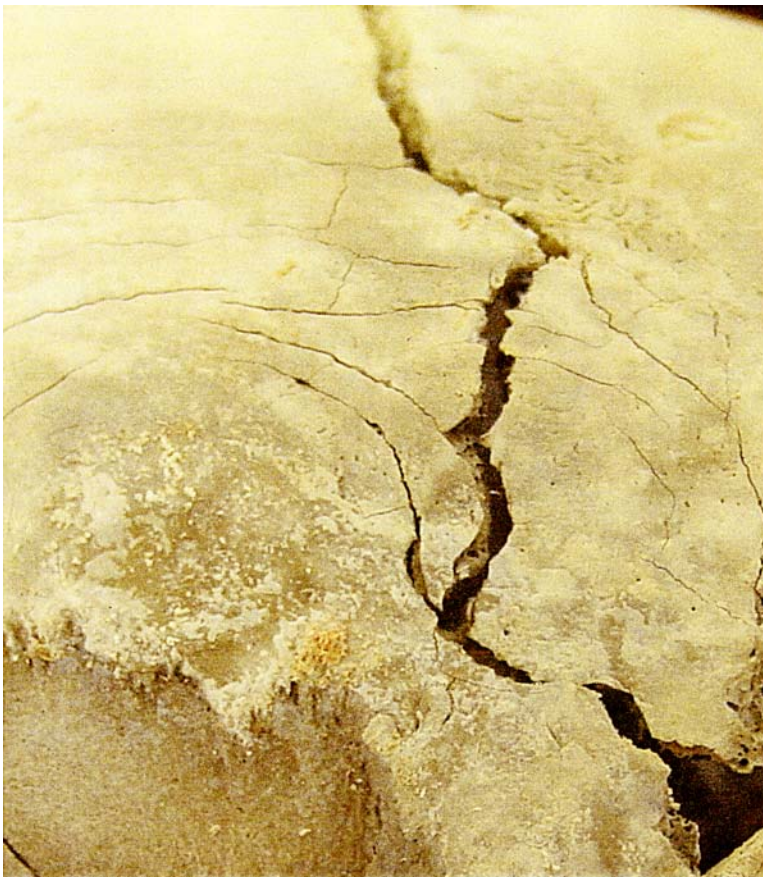
FIG. 4—(left) Heat-related fractures have well-defined sharp corresponding margins. (right) Preexisting traumatic fractures have eroded, blunted, and deformed margins from prolonged thermal exposure.



heat fractures align more precisely than traumatic fractures that are permanently distorted and eroded by heat.

Other heat-related fractures seen in cranial bone are the patina and curved tissue regression. Patina is a crazing and shrinking (much akin to old porcelain glazes) of thin superficial cortical bone most commonly seen over trabecular or diploic structures (20). Impact or rough handling of fragile calcined remains can convert the patina into delamination or complete fragmentation. Curved tissue-regression fractures, typified in long bones as an indicator of fleshed remains, are a signature of burning direction along the shaft (11). Their presence in cranial bone is identical where retractions of bulky soft tissue and periosteum permanently watermark bone with a series of semicircular arcs as exposed bone reacts to heat.

### Exploding Skull

Another association with non-traumatized heads is a belief that burning skulls will explode into small fragments if preexisting openings from ballistic or blunt force injuries are not present to relieve steam pressures from the heated brain (Fig. 5). Rationalization of this theory compares the undamaged head to an egg or potato exploding if heated without punctures for the release of steam. Conversely, the presence of preexisting trauma allegedly helps maintain structural integrity and does not explode since steam should escape through traumatic defects or fractures. These dichotomous appearances of the skull are purportedly important diagnostic indicators of preexistent trauma in the post-fire condition. This dangerous assumption potentially discourages further investigation if one accepts the fragmented or “exploded-looking” skull as proof for the absence of preexisting trauma. Such oversight dismisses the impor-



FIG. 5—The “exploded appearance” of the skull.

tance of restoration techniques that may identify signature patterns of injury from ballistic or blunt force trauma.

Controlled observations of ten non-traumatized heads on intact bodies clearly demonstrate that as soft tissue burns away, heat simultaneously destroys the organic composition of bone and internal structures of the lipid-rich brain. During firings, none of the skulls “exploded,” but rather were affected by ordinary events typical of fire scenes such as falling debris, heat embrittlement, fire extinguishments, handling, and transport. External events and the brittle mechanical properties of the thermally altered bone create the appearance of the “exploded skull” (Fig. 6). Heat affects the inorganic mineral component through deformation, shrinkage, fracturing, and fragmentation. The most common example of this is seen in delamination, where the outer table separates from the inner table and diploe, leaving fragments to fall and litter below the skull. While fragile enough to fracture from their own weight, destruction of calcined bone increases when external forces are applied.

Taphonomic factors typically present at fire scenes may create the “exploded” appearance; for example, the pressure and shock of a coldwater stream against fragile bone may produce this “exploded” look by displacing and projecting cranial fragments if directly hit. Additionally, collapse of building materials onto the body (floor, walls, ceiling) can cause further mechanical fracturing. Recovery and transportation artifacts are the final contributors to cranial fragmentation. Skeletal remains are camouflaged among similar-looking burned debris in addition to the fragmentation and taphonomy. Without archeological techniques incomplete salvage is frequent, and only larger, more identifiable elements selected for recovery. Finally, transportation from the scene to the lab creates additional artifacts with the handling and movement of unstabilized burned bone. All of these contribute to the final “exploded” appearance of the skull, whether observed in the lab or at the scene. Recovery and reconstruction of all cranial fragments are necessary to accurately rule out or identify the presence of traumatic injury.

### Common Traumatic Signatures in Burned Bone

Features of traumatic injuries were easily evaluated during most stages of burning. Any compromise in skin integrity prematurely exposes bone to thermal destruction, where sites of penetration, cut marks, or lacerations open early and focus damage much like the effects of advanced decomposition around a perimortem injury. Continual observation provides an opportunity to observe the progressive effects of heat on the blunt, sharp, and ballistic trauma in cranial bone (Table 2).

Common to both ballistic and blunt force injuries, skin lacerations prematurely and focally opened from rapid shrinkage of elastic skin over cranial bone. Accelerated exposure of traumatized areas of entrance, exit, or impact sites prematurely initiates the process of organic degradation to bone seen in stages of color changes earlier than in exposure of non-traumatized areas. During early stages, preexistent linear fractures undergo little change during the color ranges of unburned, initial buff, black charring; however, these fractures become difficult to assess as margins gradually become beveled, ragged, blunted, deformed or otherwise altered when transitioning into calcined bone. Hot vaporized organic material in bone and soft tissue undergoes pyrolysis, venting through the wound and associated traumatic fractures, impregnating the margins with black carbon—a feature of preexisting trauma, especially in earlier stages of burning organic material (Fig. 7). In the advanced stages of inorganic calcined bone, these fractures expand and permanently deform from heat as sustained incineration causes warping, shrinkage,

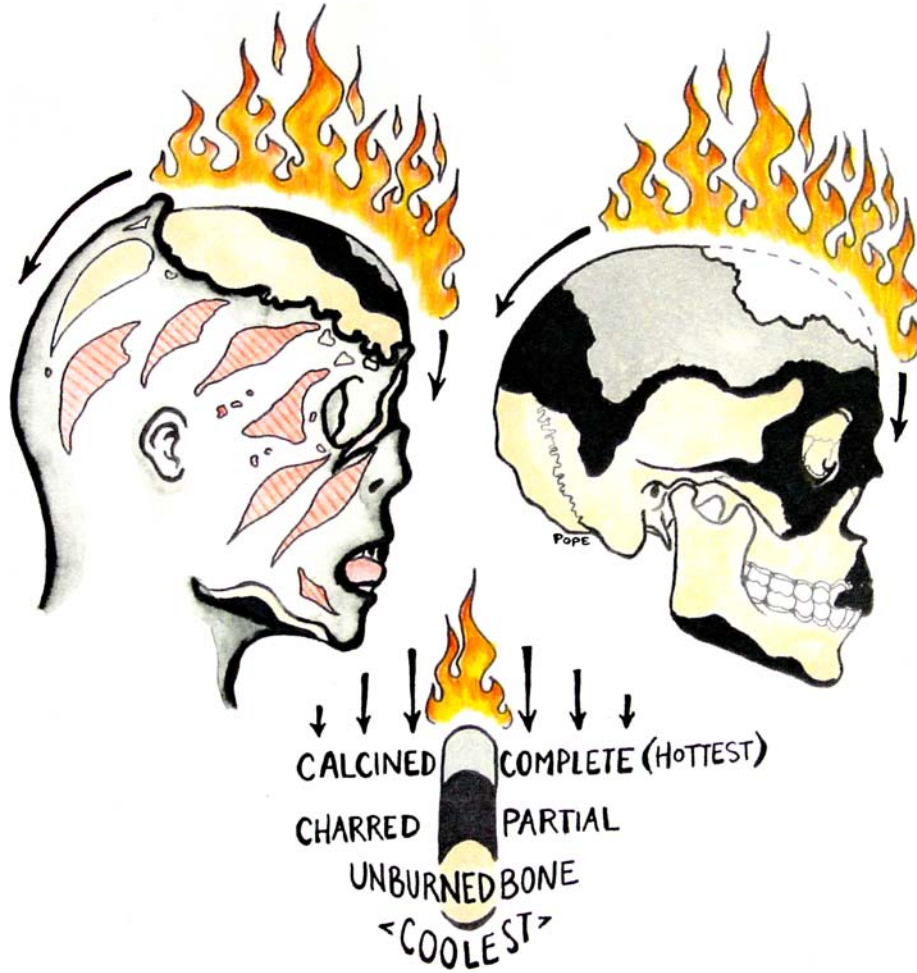


FIG. 6—Once soft tissue burns away, calcined bone of the vault becomes brittle and fragmentary from prolonged heat exposure.

TABLE 2—Summary of differential heat effects for heads with and without traumatic injuries.

Number	Treatment	Heat-related Changes During Burning	Signatures of Trauma Type in Burned Cranial Bone
16	ballistic	Wounds retract and shrink focally to expose bone. Exposed injuries undergo advanced thermal destruction. Open injuries accelerate color changes to bone.	Internal or external beveling from penetration. Secondary radiating or concentric fractures from impact. Organic carbonized venting of wounds or linear fractures. Juxtaposition of color in adjacent fragments. Radiating fractures into green bone. Extremely deformed, ragged, or eroded fracture margins. Lead wipe or pellets embedded in bone upon X-ray.
8	blunt	Edged-weapons may create open wounds in skin. Crushing injuries may weaken skin, no open wound. Impact sites retract and shrink focally to expose bone. Exposed injuries undergo advanced thermal destruction. Open injuries accelerate color changes to bone.	Impact sites with tool marks or inwardly crushed bone. Secondary radiating or concentric fractures from impact. Organic carbonized venting of wounds or linear fractures. Juxtaposition of color in adjacent fragments. Radiating fractures into green bone. Extremely deformed, ragged, or eroded fracture margins. Depression, inward crushing, patterns, tool marks.
6	sharp	Heat causes margins of soft tissue injury to bulge; this is different than heat-related skin splitting. Incisions retract and shrink focally to expose bone. Exposed injuries undergo advanced thermal destruction. Open injuries accelerate color changes to bone.	Linear incisions, depressions, cuts, chops, toolmarks, partial saw marks, complete saw marks, punctures, stabs, hacks, drill marks, etc. Features of perimortem tool marks cannot be replicated in or mistaken for stay postmortem marks in dry calcined bone.
10	control	Heat creates color changes, blistering, and skin splitting. Elastic skin exposes bone earliest in thinnest areas. Skin, fat, and muscle burn according to thickness. Bone changes colors according to exposure to heat.	Heat creates delamination, well-defined heat fractures, fragmentation, embrittlement, and color changes. “Exploded appearance” is created by heat fragmentation, fallen debris, extinguishment, movement, recovery.





FIG. 7—Venting organic material permanently impregnates preexisting traumatic fractures and openings in cranial bone.

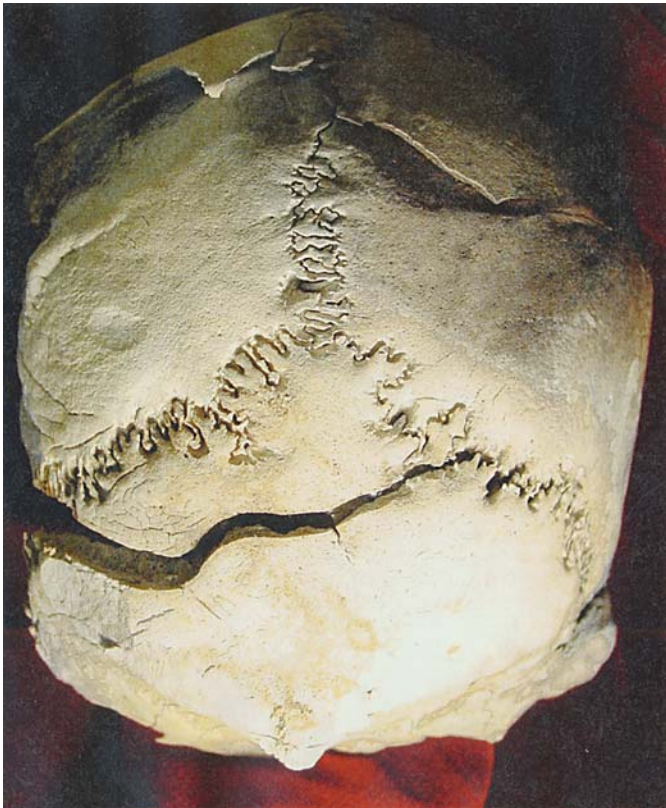


FIG. 8—Prolonged exposure to heat causes preexisting traumatic fractures to deform in size, shape, and dimensions.

and additional fracturing at the margins (Fig. 8). These changes are more advanced than non-traumatized areas due to premature and prolonged exposure to heat versus those protected longer by soft tissue.

Reconstructing burned cranial fragments allows for valuable pattern analysis of features such as fractures and color to detect preexisting injury. Finding contrasting colors in adjacent fragments is an important visual indicator that bone had fragmented and burned to different stages as separate pieces during the fire (Fig. 7). Full cranial reconstruction can also reveal convergence of radiating fractures, discontinuities in bone, or wound morphology otherwise missed in examining isolated fragments alone. Any fracture radiating into green unburned bone must be considered as traumatic in origin or created by impacting debris during the fire, but not by burning alone. Traumatic fractures progressing into green bone can be visually examined in both complete and fragmentary remains of partially incinerated bone. In the absence of sufficient vault fragments, the cranial base is often well preserved (33) and can be examined for secondary radiating fractures as evidence of preexisting trauma as seen in several ballistic specimens (Fig. 3). Traumatic features in burned bone should not be examined purely in isolation, but within the context and events of the crime scene as contributory evidence.

One of the more difficult aspects of examining burned cranial bone is created by thermal delamination of the external table since it can exaggerate, obfuscate, or destroy features of trauma. Whether thermally or mechanically induced, loss of the external cranial surface can obscure the familiar signatures of injury. For both ballistic and blunt force trauma, recovery and reconstruction of burned cranial bone are vital for determining the presence or absence of preexisting trauma in fire-related deaths.

### Ballistic Trauma

Traumatic injuries of ballistic penetration of skin and bone were documented using 16 fleshed heads involving 17 wounds of entrance and 9 wounds of exit, followed by reconstruction of burned cranial remains. Following reconstruction of 13 surviving specimens, features of entrance, exit, and associated ballistic trauma



(22–25) are recognizable and interpretable in burned bone. Even in calcined remains, entrance wounds retain their external circular shape and internal bevel. However, extreme caution is warranted if thermal delamination of the external table is misinterpreted as external beveling around the wound. When difficult to determine externally, confirmation may be obtained by looking for any internal beveling at the entry site. In early stages of incineration, fracture margins may become distinctively blackened from carbonized organic impregnation during venting. Advanced incineration may cause preexisting fracture margins to deform in shape, size, and orientation, making precise reconstruction of fragments difficult.

Large linear fractures were found as both heat-related and as radiating secondary fractures of traumatic injury. Large linear fractures should be signals to look for extensions into green bone or deformed eroded fracture margins during trauma analysis. Additionally, convergent radiating or terminating fractures will lead back, it is hoped, to the primary ballistic fractures with their internal or external beveling. It is important to identify multiple or corroborative indicators of traumatic injury rather than speculate from isolated fractures that may in fact result from heat.

### **Blunt Force Trauma**

Similar to the ballistic study, we examined eight heads with both anterior/posterior and medial/lateral sites of impact for blunt force trauma. Skulls were radiographed prior to and following trauma to document the location and extent of fractures in the skull hidden by the skin prior to burning. Each head was photographed during burning; seven surviving skulls were reconstructed and compared with radiographs for the expected versus actual fracture patterns.

Edged-weapons create defects in skin that open prematurely as heat causes the elastic skin over cranial bone to shrink rapidly. Blunt trauma behaves similarly, although seldom breaking the skin it is weakened through crushing. Impact sites with inwardly crushed bone and radiating fractures (26–28) were similar to ballistic injuries with heat rapidly destroying the organic material in bone and advancing the stages of cremation relative to other areas. These features are easily lost in heat-related fragmentation or delamination and should be looked for carefully when trying to identify blunt force signatures. Though more subtle to the eye, characteristic features of impact sites—depressions in bone, inward crushing, and margins from edged weapons—can survive cremation.

### **Sharp Force Trauma**

Sharp force injuries of skin and bone were placed in six heads and reconstructed after burning. Aside from classic ballistic injuries, sharp force trauma in bone is the easiest to recognize during the post-burn analysis. As stated above, incised wounds opened prematurely from rapid shrinkage of elastic skin over cranial bone and differentially exposed injuries to burning first. Remarkably, the burning process did not significantly alter the morphology of sharp trauma modifications in bone. Each injury was visually identifiable as uniform linear depressions or incisions in the external table. Morphologic differences were easily distinguishable among superficial scalpel incisions, deep knife wounds, and saw marks (29,30).

It is important to note that toolmarks of sharp or edged weapons in fresh bone could not be replicated in inorganic calcined bone. Burning so alters the material properties from viscoelastic to brittle that when the same edged instruments were used to duplicate toolmarks in calcined bone, a distinct polishing and spalling effect was created along the walls and floor of the trenched defect. Pressure of

the instrument superficially compacts bone, filling in heat-related fissures and fractures with fine chalk-like bone dust and polishing bone along all surfaces of each mark or strike. These postmortem features are visible under a  $\times 10$ – $\times 40$  microscope and readily distinguishable from preexisting trauma created in fresh bone. Therefore it is not possible to confuse postmortem stray marks created during the recovery or handling process with true perimortem toolmarks in bone.

### **Discussion**

The advantage of using experimental research over clinical examples is the ability to directly observe and document the burning process towards defining useful stages to establish norms and recognize deviations from the expected burn patterns of the head. Based on direct observation it is no longer correct to assume heat causes the human head to explode. Using this visual assessment to determine the presence or absence of traumatic injury may discourage further analysis and restoration techniques that recover signatures of traumatic injury in bone. We also realized that distinct characteristics of ballistic, blunt, and sharp force trauma can survive varying degrees of thermal degradation. Employing careful recovery and reconstruction techniques brings the diagnostic areas of inwardly crushed bone, ballistic and blunt beveling, features of impact sites, and sharp margins from edged-weapons into evidence.

Analysis of ballistic and blunt force trauma followed by burning is further complicated by delamination and fragmentation of primary trauma sites due to early and prolonged exposure to heat. In the absence of secondary fractures the diagnostic features of impact sites—shape, diameter, beveling, or crushing injuries—may be lost to interpretation. Identifying secondary fractures requires observation, examination, and reconstruction to see the features of unexpectedly deformed margins, blackened and eroded margins from organic venting, heat fractures originating from calcined margins, juxtaposition of color from different thermal environments, or fractures radiating into green bone; all are indications of fractures preceding the thermal events. Suspected features should be closely inspected and visually compared with a range of known postmortem heat or mechanical fractures surrounding the area of interest and with the overall condition of the skull.

Toolmarks and sharp trauma in fresh bone survived the firing process with preservation of class features and minimal deformation. Beveled margins of sharp injuries or edged-weapons in fresh bone retained diagnostic features throughout all stages of burning and were easily distinguishable from postmortem stray toolmarks in calcined bone evidenced by artificial polishing and spalling bone dust.

Despite the survivability of many traumatic signatures in bone, the harsh dynamics of the burning environment, extinguishment methods, collapse of debris, and improper or incomplete recovery techniques can obscure or destroy them. Under such influences the likelihood of finding trauma signatures diminishes when compared to unburned bone. The investigator must strive to recognize the multiple indicators of primary or secondary features of preexisting injuries as supportive evidence during trauma analysis. To do so effectively requires definitive knowledge of how human remains burn.

### *Acknowledgments*

We are standing on the shoulders of supportive people who generously donated their time and resources developing this research. Our greatest appreciation goes to Janice Hepler, Timothy James, Chris

Cox, and the supportive staff at Medical Education Research Institute for their dedicated service and collaboration. Special thanks also go to the ongoing involvement with the staff of the Shelby County Medical Examiner's Office.

Years of gratitude will be expressed to Dr. Jerome C. Rose and the faculty of the University of Arkansas, Anthropology Department, who will cultivate this beyond a dissertation topic. We would like to thank Dr. Walter Klippel, Dr. Richard Jantz, and Dr. Lee Meadows-Jantz for their involvement and support at the University of Tennessee. Finally, we are in debt to the anonymous yet prestigious awards by the Forensic Sciences Foundation for supporting and realizing the value in this work.

## References

1. Baby RS. Hopewell cremation practices. *Ohio Historical Society Papers in Archaeology* 1954;1:1–17.
2. Binford LR. An analysis of cremations from three Michigan sites. *Wisconsin Archaeologist* 1963;44:98–110.
3. Buikstra JE, Goldstein L. The Perrins Ledge Crematory Illinois State Museum Report of Investigations No. 28 Illinois Valley Archaeological Program Research Papers Vol. 8, Springfield, IL, 1973.
4. Glassman D, Crow R. Standardization model for describing the extent of burn injury to human remains. *J Forensic Sci* 1996;41:152–4. [\[PubMed\]](#)
5. Spitz W. Thermal injuries. In: Spitz, Fisher, editors. *Medicolegal investigation of death*. Springfield, IL: Charles C. Thomas Press, 1993;413–42.
6. Di Maio D, Di Maio V. *Forensic Pathology*. Boca Raton, FL: CRC Press, 1989.
7. Herrmann N, Bennett J. The differentiation of traumatic and heat-related fractures in burned bone. *J Forensic Sci* 1999;44(3):461–9. [\[PubMed\]](#)
8. de Gruchy S, Rogers TL. Identifying chop marks on cremated bone: a preliminary study. *J Forensic Sci* 2002;47(5):933–6. [\[PubMed\]](#)
9. Mayne P. The identification of precremation trauma in cremated remains. (M.A. thesis) University of Alberta, 1990.
10. Warren MW, Schultz JJ. Post-cremation taphonomy and artifact preservation. *J Forensic Sci* 2002;47(3):656–9. [\[PubMed\]](#)
11. Buikstra JE, Swegle M. Bone modification due to burning; experimental evidence. In: Bonnichsen R, Sorg M, editors. *Bone modification*. Orono, Maine University of Maine, 1989;247–58.
12. Shipman P, Giraud F, Schoeninger M. Burnt bones and teeth: an experimental study of color, morphology, crystal structure, and shrinkage. *Archaeological Sci* 1984;11:307–25.
13. Nelson R. A microscopic comparison of fresh and burned bone. *J Forensic Sci* 1992;37(4):1055–60. [\[PubMed\]](#)
14. Murray K, Rose J. The analysis of cremains: a case study involving the inappropriate disposal of mortuary remains. *J Forensic Sci* 1993;38(1):98–103. [\[PubMed\]](#)
15. Mayne-Correia P. Fire modification of bone: a review of the literature. In: Haglund W, Sorg M, editors. *Forensic taphonomy: postmortem fate of human remains*. Boca Raton, FL: CRC Press, 1997;275–93.
16. Bennett JL, Benedix DC. Positive identification of cremains recovered from an automobile based on presence of an internal fixation device. *J Forensic Sci* 1999;44(6):1296–8. [\[PubMed\]](#)
17. Ubelaker D, Owsley D, Houck M, Craig E, Grant W, Woltanski T, et al. The role of forensic anthropology in the recovery and analysis of Branch Davidian compound victims: recovery procedures and characteristics of the victims. *J Forensic Sci* 1995;40(3):335–40. [\[PubMed\]](#)
18. Krogman W, Iscan Y. *The human skeleton in forensic medicine*. Springfield, IL: Charles C. Thomas, 1989.
19. Ubelaker D. *Human skeletal remains excavation, analysis, interpretation*. 2nd ed., Washington, D.C. Smithsonian Institution Taraxacum, 1989.
20. Stewart TD. Burned bones. In: *Essentials of Forensic Anthropology*. Springfield, IL: Charles C. Thomas Press, 1957;59–68.
21. Richards NF. Fire investigation—destruction of corpses. *Med Sci Law* 1977;17:79. [\[PubMed\]](#)
22. DiMaio D, DiMaio V. *Gunshot wounds: practical aspects of firearms, ballistics, and forensic techniques*. 2nd ed. Boca Raton, FL: CRC Press, 1999.
23. Smith OC, Berryman HE, Lahren CH. Cranial fracture patterns and estimate of direction from low velocity gunshot wounds. *J Forensic Sci* 1987;32(5):1416–21. [\[PubMed\]](#)
24. Dixon DS. Pattern of intersecting fractures and direction of fire. *J Forensic Sci* 1984;29(2):651–4. [\[PubMed\]](#)
25. Rhine SJ, Curran BK. Multiple gunshot wounds to the head: an anthropological view. *J Forensic Sci* 1990;35(5):1236–45. [\[PubMed\]](#)
26. Fenton TW, deJong JL, Haut RC. Punched with a fist: the etiology of a fatal depressed cranial fracture. *J Forensic Sci* 2003;48(2):1–5.
27. Galloway A, editor. *Broken bones*. Springfield, IL: Charles C. Thomas Press, 1999.
28. Sauer NJ. Manner of death: skeletal evidence of blunt and sharp instrument wounds. In: Rathbun T, Buikstra JE, editors. *Human identification: case studies in forensic anthropology*. Springfield, IL: Charles C. Thomas Press, 1984;176–84.
29. Walsh-Haney HA. Sharp-force trauma analysis and the forensic anthropologist: techniques advocated by William R. Maples, Ph.D. *J Forensic Sci* 1999;44(4):720–3. [\[PubMed\]](#)
30. Humphrey JH, Hutchinson DL. Macroscopic characteristics of hacking trauma. *J Forensic Sci* 2001;46(2):228–33. [\[PubMed\]](#)
31. Mann RW, Bass WM, Meadows L. Time since death and decomposition of the human body: variables and observations in case and experimental field studies. *J Forensic Sci* 1990;35(1):103–11. [\[PubMed\]](#)
32. Rodriguez WC, Bass WM. Decomposition of buried bodies and methods that may aid in their location. *J Forensic Sci* 1985;30(3):836–52. [\[PubMed\]](#)
33. Bohnert M, Rost T, FallerMarquardt M, Ropohl D, Pollak S. *Fractures of the base of the skull in charred bodies—postmortem heat injuries or signs of mechanical traumatization?* *Forensic Sci Int* 1997;87: 55–62. [\[PubMed\]](#)

Additional information and reprint requests:

Elayne J. Pope, M.A.  
Department of Anthropology  
University of Arkansas  
330 Old Main  
Fayetteville, AR 72701  
E-mail: ebone50@hotmail.com