

EXPLODING SKULLS

and other myths about how the human body burns

“What is remarkable is that so little is known about the physiology of burning human remains, especially that which would interest fire investigators and homicide detectives.”

Elayne J. Pope, M.A., O. C. Smith, M.D., Timothy G. Huff, M.A.

Over the millennia, many cultures have disposed of human remains through the use of fire. Cremation today is a common method and the funerary choice of many. What is remarkable is that so little is known about the physiology of burning human remains, especially that which would interest fire investigators and homicide detectives. Literature on the subject is scant, possibly because the availability of donor human cadavers and interest by researchers never really meshed until recently. Several have explored the effects of burning through experimentation^{1,2}, clinical observation^{3,4}, and specialized studies via the cremation industry^{5,6,7}. Much still remains misunderstood about actual processes responsible for creating the final condition in burned bodies and comes as no surprise that myths developed to explain certain phenomena. Our dearth of understanding in the fire investigative community is not an exception⁸. This paper is intended to address some myths and report on recent experimental results performed using hu-

man cadavers. These experiments were conducted over the last two years in Memphis, Tennessee by first author, Elayne Pope as dissertation research under the guidance and participation of the second author, Dr. O. C. Smith, Shelby County, Tennessee Medical Examiner, and participation by the third author, Timothy G. Huff.

Each year thousands die in the United States as a result of burn injuries from accidental fire deaths as well as homicides and suicides^{3,4,8}. The environments in which these deaths occur are varied. Postmortem examination of the body identifies manner of death through external, internal, and microscopic analyses. External exams document burn patterns of soft tissue and bone, body posture, and look for evidence of preexisting trauma or associated physical evidence (restraining ligatures, weapons, or materials enclosing the body). Internal and microscopic examinations target evidence of antemortem vital responses such

as seared tissues and soot in the nose, throat, trachea, bronchioles, or lungs as an indicator of smoke inhalation, and elevated carbon monoxide levels in the blood stream from breathing during the fire^{3,4,8}. In contrast, synonymous absence of heat-related damage to internal airways and complete lack of elevated carbon monoxide levels relates that death occurred prior to the fire^{3,4,8}. Additional supporting evidence such as bullets, weapons, wounds, internal hemorrhaging, or other evidence of trauma indicates foul play with death preceding or during burning. Bodies of living victims can have mixtures of antemortem and postmortem burn injuries, whereas prior deceased victims will show predominantly postmortem burn patterns lacking vital responses of living tissues. A qualified forensic pathologist or medical examiner can differentiate these features as related to manner of death. The most commonly encountered fire deaths include victims (sometimes multiple victims) in structure and vehicle fires. On other occasions multiple fire casualties may be encountered involving motor vehicle chain-reaction collisions, aircraft crashes, or other mass disasters¹⁰. Collaborative specialists of forensic pathologists, anthropologists, odontologists, engineers, and chemists provide multi-disciplinary strengths to complex scenes involving reconstruction, analysis, and identification of multiple victims.

All fire investigators know that murderers will sometimes burn a body in order to prevent or delay the identification upon discovery. Additionally the body may also be burned in an attempt to destroy evidence¹¹. In some cases fire investigators encounter vicious homicides such as filicides where parents kill their own children with the use of fire¹². With so many deaths from fire it is very important for the fire investigator to be equipped with the latest research findings to aid in the formulation of accurate conclusions as to what happened at the scene.

This paper addresses some myths and calls attention to several characteristics of burning human flesh, focusing on burn patterns of skin, fat, muscle, and bone of the head and body. The unique burn patterns of each area of the body (head, arms, legs, and torso) makes it possible to use pattern analysis of burn injury, color changes, and fractures in bone to identify the presence or absence of preexisting traumatic injury or suspicious circumstances in human remains burned beyond recognition.

TISSUES OF THE BODY

In closest proximity to the earliest effects of heat, the body's broad surface of skin is the first layer affected by burn injuries. Skin is the largest organ in the body composed of two major layers, the epidermis and dermis. The epidermis is the thin waterproof outermost layer and the dermis is an underlying thicker inner layer containing blood vessels, hair follicles, sweat and oil glands, and layered cells for tissue replacement. Below the dermis is the hypodermis, a subcutaneous layer composed of connective and adipose (fatty) tissues covering muscle and bone [9]. The muscular layers lying deep to the skin and hypodermis cover much of the body regions (head, arms, torso, legs) and their unique configuration contribute to the varying depths of tissue protecting the underlying bones. As these layers of tissues, insulating or protecting bone, burn away, it is easy to understand how the thinner layers overlying the ankle joint exposes underlying bone more quickly than the thicker heavily muscled thigh. Therefore, under uniform exposure to heat, bones with less soft tissue protection (like the forehead or hands) become exposed to burning earlier with more extensive thermal destruction than the deeply embedded bones of the thigh and lower torso. This concept of thick and thin protection allows us to establish an expected pattern of how the human body burns.

The uniformity of major tissues (skin, fat, muscle, and bone) burn in predictable patterns based on their unique material properties and their relationship to one another within the body. Similar to evaluating the destruction to a wall with varying layers of wallpaper, drywall, insulation, and the internal wood frame, these too burn according to

material construction, their relationship and their orientation to applied heat, and leave readable patterns for analysis by fire investigators. Burn patterns on human remains can also be evaluated since structures of the body convey similar information about the body's position, orientation, and experience prior to and during the fire event. Heat sequentially affects the exposed skin of the epidermis and dermis, exposing and consuming underlying fat, and progressively burns through layers of thick muscle. Once the covering tissues have been breached by heat, bone becomes exposed and undergoes its own unique patterns of thermal degradation. Similar to changes seen in burning wood, prolonged heat exposure changes living 'green' bone into charred, dry, and fragmentary pieces easily broken and camouflaged among debris near the body. Investigators dealing with fire deaths have always looked upon the full range of these thermal changes in bodies of burn victims, the challenge is in seeing them.

Observations at autopsy and from experimental burn research have demonstrated a consistent sequence of thermal changes for skin, fat, muscle, and bone throughout the burning process until full cremation. Early changes in skin from heat cause layers of the dermis and epidermis to become waxy, glossy, blister, tighten and with progressive color changes of red, yellow and brown to black from charring. During this initial reaction to heat the skin continues to tighten, shrink, and pull apart creating transverse, longitudinal, and stellate (star-shaped) skin split patterns of the dermis and epidermis (*Figure 1*). Skin gaps then widen to expose the underlying fat, tendons, ligaments, and muscle to thermal destruction. Fat melts or renders and acts as a source of fuel^{1,2,13}. Muscle chars and burns away but also shrinks or contracts, physically moving joints, and retracting along the bone. As these protective layers are progressively destroyed, bone becomes exposed and begins its unique sequence of color and structural degradation.

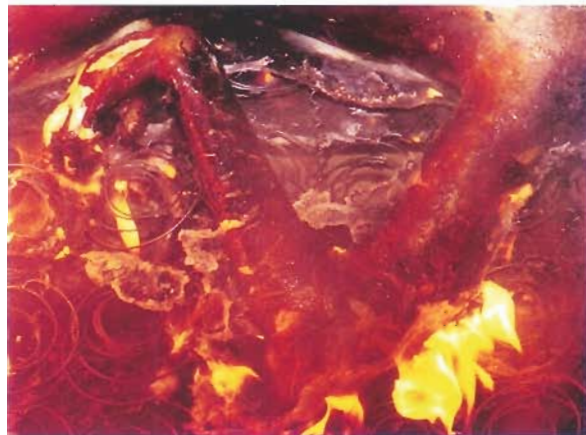
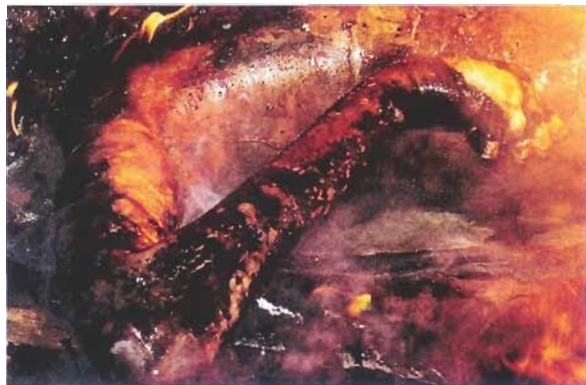
Figure 1—Early heat-related changes of colors, blisters, skin splitting, and flexure of limbs.



Bone directly affected by heat begins to degrade from pyrolysis of organic material expressed through color changes from buff, to carbonized black from charring, and then white to gray calcination resulting from complete combustion of the organic components of bone.

Color changes once believed to be a direct indicator of temperature ranges, are really time and temperature dependent as controlled burns [10] have demonstrated identical color ranges at low temperatures (400-5000° F) as produced at higher temperatures (1500-20000° F). Color is now understood to represent the time and temperature-dependent stages of pyrolysis, and decomposition of the organic component in bone.

The complexity of the human body causes various areas to react differently to the effects of burning. This is based primarily on anatomical relationships like proportion of soft tissue types, thickness to bone, and muscular attachments; but variables of heat exposure, and orientation of the body to the heat source are additional considerations. Prolonged heat exposure dramatically changes the physical positions of limbs by effects upon the longer, larger muscles attached across the more highly mobile joints. For extremities of the arms and legs, rapid dehydration from heat shortens tendons, muscle fibers of the more robust flexors, and produces the universally described and predictable "pugilistic posture." Arms become flexed, rotated, and drawn away from the body, while fingers tuck into the palm of the flexed wrist. Legs bend at the hip and knee under the influence of massive muscles of the leg, while the calves induce plantar flexion at the ankle. Smaller muscles of the head, neck, and back also shorten from heat to create a limited range of exaggerated arching of the spine. These postmortem changes are the normal and expected reactions to heat and used for reconstructing the body's position and orientation within the fire¹³. Obvious deviations from this expected pugilistic posture require explanation and should signal caution to the investigator as a potential indicator of preexisting trauma or artificially restricted position.

MYTHS

In addition to establishing norms about how a body reacts to heat, direct observations of the burning process also test traditionally based assumptions or myths about characteristics of burn victims. A common concept in some investigative circles holds that blisters on the skin only form if the victim was alive at the time of the fire. Experimental observations demonstrate this belief is not correct. Blisters are a result of damage to the chemical bonds of skin layers at the dermal/epidermal junction and readily form on burning skin of cadavers during early stages of cremation (Figure 2). The formation of postmortem blisters requires more intense heat exposure or a longer exposure to the same heat as needed to induce second degree blistering in living skin. Still another contradictory myth states that postmortem blisters will not be filled with fluid. Antemortem blisters contain fluid derived from the circulation, but postmortem blisters are created from a collection of moisture drawn out of tissue through heat exposure.

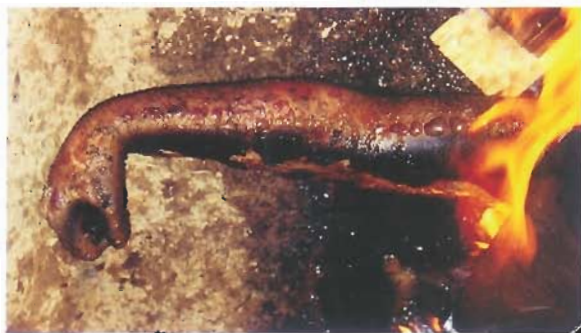

Figure 2—Heat-related blisters, charring, and splitting are skin's response to heat.

Another myth states that fingers, hands, and feet burn away in the fire, leaving only partially burned stumps of arms and legs attached to the charred torso. Due to the maximum surface area, limited protection by thin layers of soft tissues, and small bones of the fingers, hands, and lower arms, these areas are often destroyed the most rapidly and most extensively by fire. The gross visual appearance of their early destruc-

tion supports beliefs that they simply burn away, but this is not true. Fingers and hands undergo dynamic changes from heat by changing appearance as a result of powerful contraction of flexors and tendons that curl and splay fingers. Once all of the supporting soft tissues have burned away, many of the small skeletal structures of the fingers, hands, and wrists simply fragment and fall off below the body. They do not burn away and often these skeletal remains are present as fragmentary or whole bones simply camouflaged among ash and debris around the body.

When taken out of the original fire scene context, often what is seen at the medical examiner's office are the charred remains of a central torso with the partial head and partial limbs of arms and legs. The common assumption is that the absent structures burned away in the fire and this is all that remains of the individual. In fact, many of the structures considered missing or "burned off" are still present in fragmentary form at the scene and can be recovered with proper screening techniques. Typically, the largest and most recognizable parts of charred human remains are removed in haste without realizing that the remainder of the individual is still present at the scene (Figure 3). These pieces of fragmentary bone may seem insignificant, but actually can contribute valuable information about personal identity, age, and traumatic injury when reconstructed and evaluated with the rest of the body.



Figure 3—The largest and most recognizable parts of charred human remains are removed in haste without realizing fragmentary bones necessary for personal identification or trauma analysis are still present at the scene.

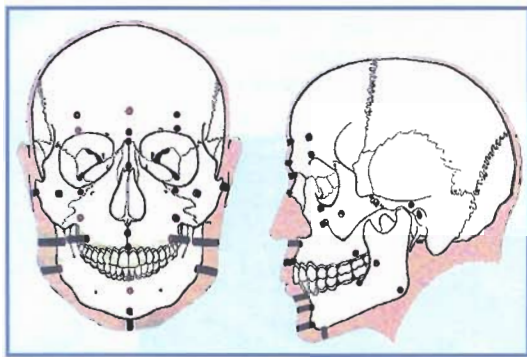
Another related myth is that the position and attitude of the body are proof of the antemortem activities of the victim, e.g., preparing to fight off or hide from an assailant or from the flames. Flexion of limbs is a natural response to heat and not entirely indicative of defensive reactions. Nevertheless, flexion alters the original body position and can become exaggerated by perimortem activities or posture (e.g. hyper flexion of the hip from sitting in a chair or vehicle). What should alert investigators is when limbs are extensively burned and lack the pugilistic posture. Environmental conditions can restrict limb movement in accidental deaths of motor vehicle fires where lower legs remain trapped under the dashboard and cannot flex. On the other hand, intentional use of restraints, like hands tied behind the back, will also restrict expected limb movement as an obvious sign of criminal action to investigators.

EXPLODING SKULL

Another widely accepted myth is that skulls exposed to intense heat explode into small fragments if preexisting openings from ballistic or blunt force injuries are not present to relieve steam pressures from the boiling brain. Volatile action within the intact skull is often compared to a potato exploding in the microwave without punctures to release steam while heated. Sensational accounts often describe seeing small fragments of skull bone scattered in the room near the remains of a headless burned body. Traditionally this has been considered the tell

tale sign of an accidental fire since the pressurized skull exploded from lack of artificial traumatic openings. Under the same misgivings, some also believe the presence of preexisting trauma helps maintain structural integrity and avoids exploding into small fragments since steam easily escapes through holes or fractures, thus leaving the entire skull intact. Either outcome, using this visual dichotomy of an intact or exploded head falsely empowers the appearance of the skull as an important diagnostic indicator of pre-existent trauma. These assumptions are dangerous since a presumptive judgment call is used to initiate or abandon a criminal fire death investigation. Such oversights may discourage further analysis and deter the investigator from utilizing recommended skull restoration techniques to effectively reveal patterns of injury from ballistic or blunt force.

Features of the "exploding skull" myth were specifically addressed using over 40 cadaver heads, either attached to intact bodies or as isolated anatomical specimens¹⁴. All the soft tissues and bones of the head experienced similar changes as follows. Wide superficial areas of skin tighten, blister, and split from heat exposure. Thinner areas of skin



over the forehead and scalp will gape open to expose wide surfaces of underlying cranial bone. Like the gradual disintegration of skin, fat, and muscle from heat, the bone experiences similar effects of carbonization charring and deformation. Surfaces of cranial bone directly affected by

heat begin to degrade from pyrolysis of organic material changing in color from buff to black from charring, and then to white or gray from calcination and combustion of the char. Prolonged burning dehydrates bone further to create shrinkage, heat-induced fractures, and warpage. The higher the heat flux and intensity, the faster all of these effects will occur.

Under normal conditions, thermal destruction of the head follows the principles outlined above, advancing from the top of the head downward due to the thicker protective muscle layers positioned lower on the mid-face, lower face, and neck (Figure 4). The upper areas of the forehead and scalp are minimally protected by thin soft tissues; the top of the skull (vault) is therefore usually exposed to heat earliest and longest. Prolonged heat exposure causes loss of organic material. This

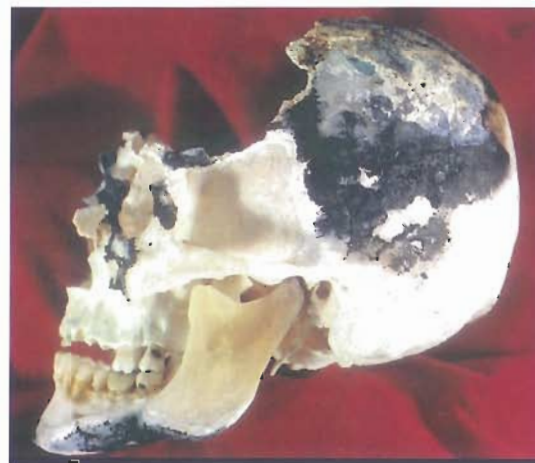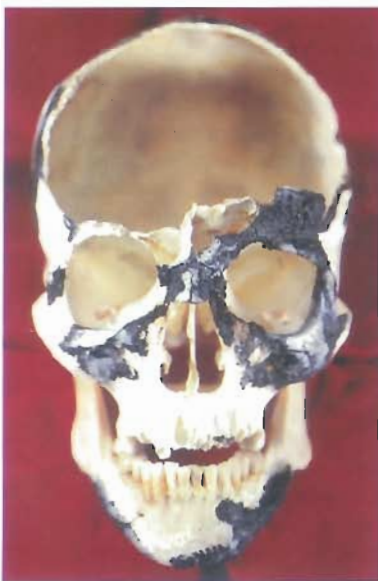


Figure 4—Burn Patterns on the skull correspond with tissue thicknesses. Thin tissues and thin bone are responsible for the "Exploded Skull" appearance.

component in living bone provides the strength, flexibility, and resistance to the mechanical stresses of daily life. When organic material is burned away, the remaining inorganic mineralized component of bone (hydroxyapatite, calcium, and phosphate) is brittle, glass-like and easily fragmented. Therefore, any external force applied to this fragile burned vault can easily result in fragmentation, especially if levered against the resistance from stronger unburned bones in the face and neck. This is the underlying mechanism for the "exploded skull" appearance.

The skull simply does not explode regardless of the presence or absence of preexisting trauma¹⁴. In all of the controlled experiments, none of the heads exploded but instead bones of the skull became progressively more brittle and fragmentary throughout each burning episode. Some fragmentation and fracturing is naturally produced as organic materials burn away and like wood, bone shrinks, deforms, and becomes brittle from prolonged heat exposure. A common heat-related fracture in cranial bone is termed delamination, where broad surfaces affected by heat shrink and peel thin bone like dried paint chips, leaving a spongy inner layer (diploe) exposed. The slightest touch to fragile burned bone can increase the effects of delamination and fragmentation. Delamination can progress through to full thickness fractures in cranial bone and sometimes produces beveled margins in cranial bone that could be mistaken for ballistic trauma. Close examination of the feature will resolve questions of the mechanism.

As a room fire progresses, falling debris can cause significant impact damage to the very fragile cranial bones. Any type of structural intrusion, contact, movement, or physical manipulation can be responsible for the fragmentation of bone (Figure 5). The greatest amount of



Figure 5—Two skulls have preexisting traumatic injury. The right skull was impacted with fallen debris and has the misleading "exploded appearance" of fragmentary cranial bone.

damage occurs during the fire with circumstances of falling debris, collapsing structures, or impact with pressurized water from a fire hose creating the "exploded" appearance of the head and displaced cranial fragment scattered throughout the room. Furthermore, unless brittle remains of the skull are chemically stabilized with shellac or polyurethane fixative, any type of movement, manipulation, or transportation can induce further destruction.

Additionally, these same destructive circumstances will produce similar fragmentation in the brittle burned skulls of murder victims. In such cases, an investigator relying upon the exploded appearance to dismiss the possibility of earlier injury may presumptively and incorrectly classify a death as fire related, that is in reality a homicide. This simple and realistic explanation of the "exploded skull" appearance is intended to shine new light on the traditional creeds taught to generations of fire investigators.

Fire destroys the normal appearance of materials, and fire investigators must look to see beyond the jungle of charred debris to interpret burn patterns for signatures of criminal activity. The same should be done with charred remains of the human body to reconstruct the environment of death. Even with severe burning, soft tissue may retain some features of internal wounds and injuries that are detectable at autopsy. When adequate soft tissue is absent in cases of advanced burning or complete incineration, only bone is left to analyze. Because the devastation of fire and collapsing debris does not discriminate impacting the fragile bone of either traumatized or intact skulls, both specimens risk being fragmented and should be reconstructed to rule out the presence of trauma.

Careful hand sifting of debris near the body through standard 1/4 inch (6.4 mm) mesh hardware cloth will recover the maximum number of bone fragments with attention to visual and textural identification differing from wood, plaster, drywall, or other construction materials. Contact of water with bone should be avoided since moisture softens and dissolves fragile calcined bone like wet chalk, furthering its destruction. For the safety of investigators, water should be used to extinguish smoldering materials surrounding the body, but not directly applied to burned tissues or bone.

PREEXISTING TRAUMA

Experimental traumatic injuries have been observed in soft tissue and cranial bone to determine how many identifying characteristics survive the process of thermal destruction to soft tissue and bone¹⁴. Despite the aggressive transformations and reduction of a body by fire, many signatures of traumatic injury remain recognizable. Characteristics of ballistic entrance and exit wounds, impact sites of blunt force trauma, and sharp force injuries with their secondary features such as radiating or concentric fractures leave a permanent signature in bone that can be reconstructed, even after burning (Figure 6). Most of these features are only recognizable after a considerable majority of the cranial vault has been reconstructed since individual fragments lack obvious information as isolated specimens. However, once these smaller fragments are joined back together like pieces of a puzzle, they can show telltale signs of traumatic injury. Therefore, recovery and collection of bone fragments is extremely important as is all physical evidence that can potentially contribute to any forensic investigation.




Figure 6—Reconstructed cranial bone shows an exit wound with external beveling, radiating fractures, and juxtaposition of color.

Once a majority of the cranial vault has been reconstructed, features such as uneven or abrupt changes in color of adjacent bone fragments may indicate that the skull did not burn as a whole part, but had prior fractures or something preventing it from burning consistently as expected. Juxtaposition of blackened, charred, or brittle white calcined fragments against green (unburned) bone indicates they were fractured,

separated and differentially exposed prior to burning as separate pieces (Figure 6). This patchwork of colors is only recognizable after reconstruction of fragments. The presence of fractures radiating from burned bone into green bone is a characteristic of perimortem (around the time of death) trauma. Despite the effectively destructive nature of fire to a body, the dynamic process of burning is not powerful enough to break strong, living, green bone protected within soft tissue; therefore such injuries preceded the fire. Many signatures of traumatic injury have been identified through these controlled experiments and demonstrate the value and benefits of reconstructing fragmentary cranial remains to assist in resolving the manner of death¹⁴.

CONCLUSIONS

Experimentation replaces speculation with fact for those who investigate and analyze fire-related deaths. While each circumstance is undoubtedly unique, the generalized effects of fire are known to produce predictable patterns on victims in both soft tissue and bone. When applied to real cases, experimental observations provide scientific strengths to the overall investigation. Observing the actual stages of destruction for soft tissues and bone under known time and temperature conditions gives us accurate information for application to individual cases. For example, a pattern of burn damage on human remains not consistent with the expected pugilistic posture should be a red flag to investigators to seek a further explanation. One such case involves a situation where the arms were intentionally bound behind the victim's back with wire, restricting the natural ability of his arms muscles to attain the normal pugilistic position. As a result, the arms could not move freely into the flexed position and had an unusual burn pattern resulting from their restricted position. And finally, cautionary tales of the exploding head include a case where the small cranial fragments found scattered around the body at a crime scene were meticulously glued back together as a large puzzle of burned bone. Based on the scattered cranial fragments (supposedly as the result of an "exploding" skull), the death was thought to be fire-caused, but final reconstruction of the cranial vault revealed distinct features of entry and exit wounds. ●

The authors would like to acknowledge the generous support from the Medical Education and Research Institute, the Forensic Sciences Foundation, and the University of Arkansas Anthropology Department. Further gratitude is expressed to John DeHaan of Fire-Ex Forensics Inc., David Iovine, PhD. at the University of Tennessee, Jerome C. Rose, PhD. at the University of Arkansas, and Special Agent Chris Hopkins, FBI Sacramento for their valuable comments and suggestions.

References

- [1] DeHaan JD. *Kirk's Fire Investigation 5th Edition* Prentice Hall 2002.
- [2] DeHaan JD, Nurbakhsh S. "Sustained Combustion of an Animal Carcass and its Implications for the Consumption of Human Bodies in Fires." *Journal of Forensic Sciences* 2001;46(5):1076-1081.
- [3] Spitz W. Thermal injuries. In: Spitz, Fisher, editors. *Medicolegal Investigation of Death*. Springfield, IL: Charles C. Thomas Press, 1993;413-442.
- [4] Di Maio D, Di Maio V. *Forensic Pathology*. Boca Raton, FL: CRC Press, 2001.
- [5] Bohnert M, Rost T, FallerMarquardt M, Ropohl D, Pollak S. "Fractures of the Base of the Skull in Charred Bodies- Postmortem Heat Injuries or Signs of Mechanical Traumatization?" *Forensic Sciences International* 1997;87:55-62.
- [6] Bohnert M, Rost T, and Pollak S. "The Degree of Destruction of Human Bodies in Relation to the Duration of the Fire." *Forensic Sciences International* 1998;95:11-21.
- [7] Eckert W, Jones S, and Katchis S. "Investigations of Cremations and Severely Burned Bodies." *American Journal of Forensic Medicine and Pathology*, 9, 1988:188-200.
- [8] Smith OC, Pope EJ "Documenting Patterns of Injury in Fire Victims," paper presented to the 55th Annual Meeting of the American Academy of Forensic Sciences, Chicago, IL. In *2003 Proceedings American Academy of Forensic Sciences* Volume 9.
- [9] Stocking JC. *Burn Injury: Initial Assessment and Resuscitation*. Air & Surface Transport Nurses Association 2003 [Online]. Available: <http://www.astna.org/burn-cel>.
- [10] Smith, OC, Pope EJ. *Burning Extremities: Patterns of Arms, Legs, and Preexisting Trauma*. Paper presented to the American Academy of Forensic Sciences, Chicago, IL. In 2003 Proceedings American Academy of Forensic Sciences Volume 9.
- [11] Sapp AD, Huff TG. *Arson-Homicides: Findings from a National Study*. National Center for the Analysis of Violent Crime, FBI Academy, Quantico, Virginia, January, 1995.
- [12] Huff TG. "Filicide by Fire." *Fire and Arson Investigator*, Journal of the International Association of Arson Investigators, June, 1993.
- [13] Pope EJ, Smith OC. "Burning Observations of the Body: Sequencing Soft and Hard Tissue Destruction". Paper presented to the American Academy of Forensic Sciences, Chicago. In 2003 Proceedings American Academy of Forensic Sciences Volume 9.
- [14] Pope EJ, Smith OC. "Identification of Traumatic Injury in Burned Cranial Bone: An experimental approach." *Journal of Forensic Sciences* 2004; 49(3).

EXPLODING SKULLS AND OTHER MYTHS ABOUT HOW THE HUMAN BODY BURNS

ABOUT THE AUTHORS—



Elayne Pope



Dr. O. C. Smith



Timothy G. Huff

Elayne Pope, MA is completing her doctoral degree at the University of Arkansas. Her dissertation explores the effects of burning to bone and tissues of the human body through experimental actualistic studies with cadaver models. This research documents continuous stages of thermal destruction to soft anatomy and its influence on underlying skeletal structures normally encountered in burned remains of forensic casework. She has taught Forensic Anthropology, Criminalistics, and Human Taphonomy through the Anthropology Department in Arkansas and holds a research appointment at the Shelby County Medical Examiner's Office in Memphis, Tennessee.

Dr. O. C. Smith received his MD from the Medical College of Wisconsin in 1978. He received training in Anatomic, Clinical and Forensic Pathology at the University of Tennessee, Memphis, followed by board certification in these three areas in 1983. Dr. Smith received training in forensic firearms examination in 1985 and is a full-time faculty member of the University of Tennessee and the medical examiner for Shelby County, Tennessee. His focus is in

forensic pathology in civilian life and the Naval Reserve involves the biomechanics of skeletal, ballistic, and blast injury, burns, and aircraft mishap investigations.

Timothy G. Huff, MA, is retired from the FBI's National Center for the Analysis of Violent Crime (NCAVA) at the FBI Academy in Quantico, Virginia. There he was a violent crime analyst with a specialty in arson-homicides. He participated in the analysis of arson, bombing and related felony cases, including threat assessments submitted to the NCAVA by law enforcement agencies from all over the United States and foreign countries. He conducted extensive research on arsonists and bombing related offenders and provided training to requesting agencies. Mr. Huff served two terms as a director of the IAAI and presently is the technical editor of the IAAI's journal, the "Fire and Arson Investigator." He is now a law enforcement consultant in California.

Battery Powered Portable X-ray

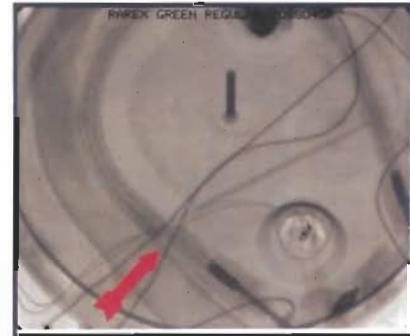
Investigate on location with a five pound X-ray unit.



Coffeemaker



XR150 X-ray unit



Radiograph of coffeemaker

Golden Engineering has been manufacturing portable X-ray units since 1973. Our products are used extensively by law enforcement personnel in security applications.



Golden Engineering, Inc.

P.O. Box 185 Centerville, IN 47330 USA
(765)855-3493 Fax (765)855-3492

www.goldenengineering.com